



PATIENT

The submitted study contained 14 videos of the gastrointestinal tract only.

Puppy Toll

PRESENTING CLINICAL SIGNS

SPECIES

Canine

- O is breeder- reports this puppy is thinner, has lost weight acutely. Energy slightly down but always "chill", reports E/D normally, still interested in food
- Bloody D₊ noted, reportedly drank mop bucket water

BREED

Springer Spaniel

Abnormal PE/Chem/CBC/UA Results: Very subdued, pink mm; hemorrhagic diarrhea noted, abdomen- not overtly painful but palpated thickened area- r/o intussusception vs other Parvo negative, no other puppies ill Recommended full US, CBC/Chem- declined

SEX

ULTRASONOGRAPHIC EXAMINATION OF THE ABDOMEN

M

Gastrointestinal

The stomach contained a moderate amount of non-shadowing ingesta.

AGE

11wk

Confirmed small intestinal intussusception in the mid to cranial abdomen and located caudal to the stomach. Adjacent intestinal segments exhibited intact wall layering with maintained wall layer ratio and empty lumen indicating non-obstructive intussusception.

WEIGHT

10-15lb

Free Abdomen

Intermittent mildly prominent to enlarged mesenteric lymph nodes were present. The lymph nodes were essentially isoechoic to adjacent omentum without evidence of peripheral inflammation and maintaining a normal width: length ratio (<0.5).

INTERPRETED BY

R. McKenzie Daniel,
DVM, DABVP
(Canine and Feline)

Pockets of minor peritoneal effusion were present.

ULTRASONOGRAPHIC FINDINGS

Primary

- Confirmed small intestine intussusception
- Retained non-shadowing gastric ingesta consistent with food echogenicity
- Intermittent mild mesenteric lymphadenopathy and scant peritoneal effusion consistent with lymphatic hyperplasia or immunologic immaturity and physiologic effusion

HOSPITAL NAME

State Avenue Vet
Clinic

INTERPRETATION OF THE FINDINGS & FURTHER RECOMMENDATIONS

Surgical consultation is recommended.

REFERRING VET

Dr. Jessie Evoniuk

INVOICE

23810

DATE

02/05/2026



PATIENT

Puppy Toll

SPECIES

Canine

BREED

Springer Spaniel

SEX

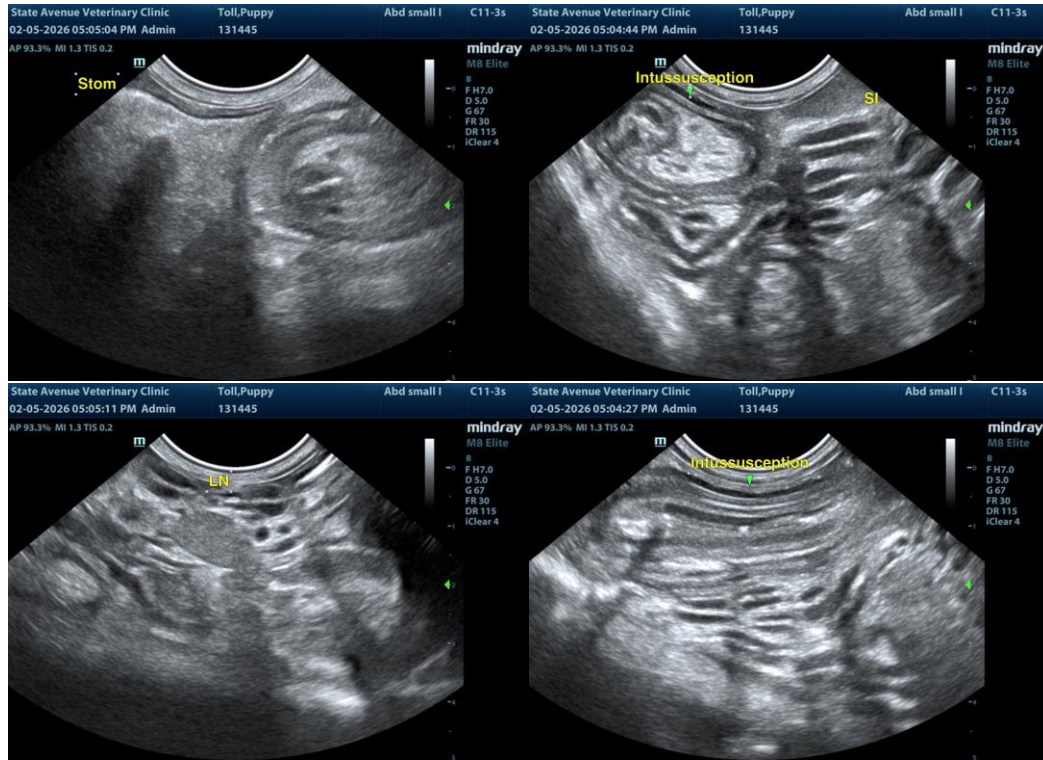
M

AGE

11wk

WEIGHT

10-15lb



INTERPRETED BY

R. McKenzie Daniel,
DVM, DABVP
(Canine and Feline)

IMAGING PERFORMED BY

Dr. Jessie Evoniuk

HOSPITAL NAME

State Avenue Vet
Clinic

REFERRING VET

Dr. Jessie Evoniuk

INVOICE

23810

DATE

02/05/2026

The information and recommendations provided are based on the images presented by the referring veterinarian/sonographer. No evaluation can be communicated regarding pathology that was not visible in the image/video clips provided.

Thank you for this referral. If the clinical or image interpretation does not parallel your findings or if I can be of any further assistance, please contact me.

R. McKenzie Daniel, DVM, DABVP (Canine/Feline Practice)
info@sonopath.com